

Sporadic Renal Angiomyolipoma: Can We Adopt a Uniform Management Protocol?

Angiomiolipoma renal esporádico: ¿Podemos adoptar un protocolo de tratamiento estándar?

Mussammet Ahmed¹ Hong Teo² Tariq Sami¹ Ugo Otite¹

¹Department of Urology, Sandwell and West Birmingham NHS Trust, West Midlands, United Kingdom

²Department of Radiology, Sandwell and West Birmingham NHS Trust, West Midlands, United Kingdom

Address for correspondence Mussammet Ahmed, MBBS, MRCS, FRCS, Department of Urology, Sandwell and West Birmingham NHS Trust, KINGSTON HOUSE, 438-450 High St, West Bromwich B70 9LD West Midlands, United Kingdom
(e-mail: Mussammet.ahmed@nhs.net; Dinaahmed714@hotmail.com).

Urol Colomb 2022;31(4):e177-e185.

Abstract

Renal angiomyolipomas (AMLs), formerly known as PEComas (tumors showing perivascular epithelioid cell differentiation) are common benign renal masses composed of a varying ratio of fat, blood vessels, and smooth muscles. They are largely asymptomatic and diagnosed incidentally on imaging.

The adipose tissue content is the factor that gives AMLs their characteristic appearance on imaging and makes them easily identifiable. However, the fat-poor or fat-invisible varieties, which are difficult to differentiate radiologically from renal cell carcinomas (RCCs), present a diagnostic challenge. It is thus essential to establish the diagnosis and identify the atypical and hereditary cases as they require more intense surveillance and management due to their potential for malignant transformation.

Multiple management options are available, ranging from conservative approach to embolization and to the more radical option of nephrectomy. While the indications for intervention are relatively clear and aimed at a rather small cohort, the protocol for follow-up of the remainder of the cohort forming the majority of cases is not well established. The surveillance and discharge policies therefore vary between institutions and even between individual practitioners. We have reviewed the literature to establish an optimum management pathway focusing on the typical AMLs.

Keywords

- ▶ renal angiomyolipoma
- ▶ AML
- ▶ management
- ▶ guideline

Resumen

Los angiomiolipomas renales (AML), antes conocidos como PEComas (tumores que muestran epitelioides perivascular) son masas renales benignas frecuentes compuestas por una proporción variable de grasa, vasos sanguíneos y músculos lisos. Suelen ser asintomáticos y se diagnostican de forma incidental en las pruebas de imagen. El contenido de tejido adiposo es el factor que confiere a los AML su aspecto característico en las imágenes y los hace fácilmente identificables. Sin embargo, las

received
May 11, 2022
accepted
September 20, 2022

DOI <https://doi.org/10.1055/s-0042-1759625>.
ISSN 0120-789X.
e ISSN 2027-0119.

© 2022. Sociedad Colombiana de Urología. All rights reserved.
This is an open access article published by Thieme under the terms of the Creative Commons Attribution-NonDerivative-NonCommercial-License, permitting copying and reproduction so long as the original work is given appropriate credit. Contents may not be used for commercial purposes, or adapted, remixed, transformed or built upon. (<https://creativecommons.org/licenses/by-nc-nd/4.0/>)
Thieme Revinter Publicações Ltda., Rua do Matoso 170, Rio de Janeiro, RJ, CEP 20270-135, Brazil

Palabras Clave

- ▶ angiomiolipoma renal
- ▶ AML
- ▶ manejo
- ▶ guía

variedades pobres en grasa o invisibles, que son difíciles de diferenciar radiológicamente de los carcinomas de células renales (CCR), suponen un reto diagnóstico. Por lo tanto, es esencial establecer el diagnóstico e identificar los casos atípicos y hereditarios, ya que requieren una vigilancia y un tratamiento más intensos debido a su potencial de malignización. debido a su potencial de transformación maligna. Existen múltiples opciones de tratamiento, que van desde el enfoque conservador hasta la embolización y la opción más radical de la nefrectomía. Si bien las indicaciones para la intervención son relativamente claras y están dirigidas a una cohorte bastante pequeña, el protocolo para el seguimiento del resto de la cohorte que forma la mayoría de los casos no está bien establecido. Por lo tanto, las políticas de vigilancia y alta varían entre instituciones e incluso entre profesionales individuales. Hemos revisado la literatura para establecer una ruta de manejo óptima centrada en los AML típicos.

Introduction

Renal angiomyolipomas (AMLs) are common benign renal masses composed of a varying ratio of fat, blood vessels, and smooth muscles. They are often detected incidentally and, although largely asymptomatic, a small number of cases may present with or progress to develop symptoms like pain or complications such as spontaneous bleeding. Multiple treatment options are available, but no consensus or guidelines have been agreed to manage these lesions and, more importantly, there are no established surveillance or discharge protocols. The convention is to consider treatment for AMLs larger than 4 cm, which was first proposed by Oesterling et al.¹ This has since been debated and reviewed over the years with varying size parameters proposed and additional risk factors described based on the natural history of AMLs, which will discuss through the subsequent sections of the present paper.

The current untailored varied approach among individual practitioners and institutions needs to be streamlined, backed by evidence, and protocols, established to avoid the trap of neglect, excessive surveillance, and unnecessary healthcare expenditures. We have searched the available literature on renal angiomyolipoma through PubMed and Google Scholar to review the evidence and suggest an optimal management pathway. In the present paper, we have focused on the typical AMLs, as they form the bulk of the cohort. Comparatively, the management of hereditary and atypical AMLs has been better defined, and is exemplified in the “UK guidelines for managing tuberous sclerosis complex”² and “2012 International TSC [tuberous sclerosis complex] Clinical Consensus Conference Recommendations.”³

Methodology

A literature search on AMLs was conducted on PubMed, and it included but was not limited to the terms *AML*, *Renal AML*, *Angiomyolipoma*, and *Sporadic AMLs*. Only papers published in English that involved sporadic renal AMLs were reviewed, in a total of 46 papers. Information on classification, appearance, diagnosis, presentation, risk factors and management

were analyzed to propose a pathway for surveillance of sporadic AMLs including indications for treatment.

Classification

The classification of AMLs is based on radiological features, clinical behavior, and histological characteristics.

Radiological Classification

A new imaging classification of renal AML was proposed and reported by Song et al.⁴ in 2016, based on the quantitative assessment of the AMLs on computed tomography (CT) and magnetic resonance imaging (MRI). Prior to this time, renal AMLs were generally classified as either lipid-rich or minimal fat lesions based on imaging and histopathological features. Song et al.⁴ classified AMLs into three subtypes according to the amount of fat within such lesions quantified by CT or MRI: fat-rich, fat-poor, and fat-invisible.

On unenhanced CT (UECT), fat-rich AMLs are characterized by the presence of low attenuation areas measuring -10 Hounsfield units (HUs) or less, whereas in both fat-poor and fat-invisible AMLs these areas measure more than -10 HUs on UECT.⁴ Using the chemical-shift imaging (CSI) MRI technique, which consists of opposed-phase and in-phase gradient echo sequences with signal intensity (SI) measurements, fat-poor AMLs, which contain a small amount of fat, would present a tumor-to-spleen SI ratio lower than 0.71, and an SI index greater than 16.5%. On the contrary, fat-invisible AMLs would present a tumor-to-spleen SI ratio of 0.71 or greater, and a SI index of 16.5% or lower. Hence, fat-poor AMLs may be differentiated from fat-invisible AMLs using CSI MRI.⁵⁻⁷

Therefore, care and attention are required to control the size and placement of the regions-of-interest (ROIs) during quantitative assessment of the lesions on both CT and MRI to avoid inaccurate registration of the size of the low attenuation areas on UECT and the SI on MRI, which can lead to miscalculation and consequently misclassification of the subtypes of AML.⁴ ▶ **Table 1** demonstrates the radiological features of AMLs.⁴

Rarely, renal cell carcinoma (RCC) may have a fat component, which is strongly suggestive of AML but is not

Table 1 Radiological classification of renal AMLs adapted from Song et al.⁴

	Fat-rich AML	Fat-poor AML	Fat-invisible AML
UECT ROI	≤ -10 HU	> -10 HU	> -10 HU
TSR on CSI MRI	< 0.71	< 0.71	≥ 0.71
SII on CSI MRI	> 16.5%	> 16.5%	≤ 16.5%

Abbreviations: AML, angiomyolipoma; CSI, chemical-shift imaging; MRI, magnetic resonance imaging; ROI, region of interest; SII, signal intensity index; TSR, tumor-to-spleen ratio; UECT, unenhanced computed tomography.

pathognomonic. Approximately 5% of AMLs are fat-poor and may mimic RCCs.⁸ Here, the lack of calcification on CT may favor diagnosis of AML.^{5,6} A rare variant of AML is the eosinophilic AML (eAML); first described by Eble et al.,⁹ it is characterized by predominant perivascular epithelioid cells and, radiologically, it presents distinct differences from AML but close resemblance to RCC.¹⁰ Fat-poor AMLs with high cellular content, eAMLs show variable enhancement on CT and, on MRI, high cellular content with absence of fat. Pathological bleeding, necrosis, and hyalinization contribute to the heterogeneity, making them difficult to distinguish from RCCs on imaging.¹⁰⁻¹²

Clinical Classification

While 80% of AMLs are sporadic, 20% are hereditary, associated with tuberous sclerosis (TS) or pulmonary lymphangioleiomyomatosis (LAM).^{13,14} The genetically predisposed presentations are likely to be multiple, progressive, more aggressive, and affect patients at a younger age. Hence, this potential aggressive nature must be reflected in their surveillance/management. Identification of the clinical features is helpful in differentiating hereditary cases from sporadic cases, which form the vast majority of presentations.

A total of 80% of TS patients have AMLs; TS is a multisystem, autosomal dominant condition characterized by hamartomas, mainly in the brain, lung, skin, and kidney. This occurs due to mutation of either one or both inhibitory genes, called *tuberous sclerosis complex 1* (TSC1), on chromosome 9q34, which codes for protein hamartin, and *tuberous sclerosis complex 2* (TSC2), on chromosome 16p 13.3, which codes for protein tuberin.^{15,16} As a consequence, hamartin and tuberin fail to form an inhibitory complex against mammalian target of rapamycin (mTOR). This leads to unopposed activation of mTOR, resulting in increased angiogenesis, protein synthesis, cell growth, and development of characteristic hamartomas. Tuberous sclerosis is characterized by mental retardation, neurological symptoms, epilepsy, adenoma sebaceum, and other hamartomas.

A rare disease that most commonly affects women, LAM is characterized by lung cysts and lymphatic abnormalities, chyloous pleural effusion, recurrent pneumothoraces, and cystic lung disease.^{13,17-21} The pathophysiology of its association with AML is similar to that of the association of AML and TS.

Histological Classification

Histologically, AMLs are classified as typical (triphasic) or atypical (monophasic, epithelioid). Typical AMLs are

triphasic, as they are composed of varying proportions of blood vessels (angio), smooth muscles (myo), and adipocytes (lipo). Some AMLs may be composed largely of one element and hence are described as monophasic (atypical). A variant of this is epithelioid AML (eAMLS), an AML with predominant epithelioid cells, abundant eosinophilic and granular cytoplasm, and minimal or no adipocytes. These may be aggressive with potential for malignant transformation; hence, they must be differentiated from typical AMLs to streamline management. Histologically, eAMLS may resemble RCCs, and the immunohistochemical difference is the presence of markers such as melan-A, HMB-45 (immunohistochemical test), caldesmon, and smooth-muscle actin. Generally, if more than 5% of the specimen contains an epithelioid component, then it is described as an epAML, which has a poor clinical outcome compared with typical AMLs.¹² However, it is difficult to identify malignancy in eAMLS, as not all cases with cellular atypia are malignant.¹⁰ The adverse histological features associated with malignancy have been described by two large multicenter retrospective studies^{22,23} as: a large epithelioid cell component, severe nuclear atypia, extent of nuclear atypia, mitotic count, presence of atypical mitotic figures, necrosis, presence of lymphovascular invasion, tumor size larger than 7 cm, and renal vein invasion.

Diagnosis and Imaging Modality

Presentation and Symptoms

More than 50% of AMLs present as incidental findings on ultrasound (US) or CT scans, and most are asymptomatic at diagnosis.^{18,24} Symptoms at diagnosis are present in less than 15% of cases, and they may be related to retroperitoneal hemorrhage.¹⁸ Wunderlich syndrome is a rare condition resulting in spontaneous non-traumatic renal bleed, which may be caused by renal angiomyolipoma and RCC.²⁵ In up to 10% of cases of Wunderlich syndrome, massive and life-threatening retroperitoneal hemorrhage occurs,²⁴ which is the main clinical concern. Other symptoms may include flank pain, palpable mass or painless hematuria. Studies^{13,26,27} also suggest symptoms of urinary tract infection and renal failure.^{13,26,27}

Around 80% of AMLs are sporadic, and 20%, hereditary. The latter are linked commonly to TS and LAM with symptoms and presentation as aforementioned. Here, the associated AMLs have a more aggressive tendency, and the presence of symptoms and progression are more likely. About 80% of TS patients develop AMLs, which are frequently bilateral, multifocal, and have a propensity to grow and

suddenly bleed. Patients diagnosed with LAM, however, have a high prevalence of symptomatic AMLs and should, therefore, be screened for renal AMLs at the time of diagnosis and undergo surveillance.¹⁷

A rare variant of renal angiomyolipoma, epAMLs can occur in patients with or without TS, and it may be malignant.¹¹ In a series of 437 consecutive cases of AML, the authors²⁸ identified epAMLs in 4.6% of the cases. In total, 22% of epAMLs present with invasion or metastasis with higher mitotic activity, indicating higher risk of metastasis.²⁹

Gross Appearance

Macroscopically AMLs appear as well-circumscribed fatty lumps. They may be single or multiple, unilateral or bilateral. The cut surface may display the vascular, smooth-muscle, and fatty components as red, grayish-white, and yellow respectively. The tumor may involve the intrarenal venous system, the renal vein, or the vena cava, depending on its location and size. Rarely, cystic components may also be displayed.³⁰

Radiological Features

Often observed as incidental imaging findings, AMLs can be identified on US, UECT, MRI scans, but US and CT are more commonly used.

On grayscale US scans, fat-rich AMLs are typically markedly hyperechoic comparable to the echogenicity of renal sinus fat, with posterior acoustic shadows. The hyperechoic appearance (characteristic bright echo pattern) is the US reflection from the fatty component, which varies with the amount of fat in the lesion. The acoustic shadowing is due to the tissue interfaces between the elements of the AML.²⁶ Fat-poor and fat-invisible AMLs, on the other hand, are generally less echogenic or may be isoechoic compared with the renal parenchyma. Due to overlapping sonographic features of different subtypes of AML and RCC, US scans alone cannot be used to confidently confirm the diagnosis of an AML.³¹

When a solid renal lesion has been identified, one of the key roles of imaging is to attempt to differentiate a benign from a malignant lesion and, whenever possible, to provide a specific diagnosis. While classic fat-rich AMLs are usually easy to diagnose on both CT and MRI, differentiating fat-poor and fat-invisible AMLs from RCC subtypes remains challenging, since these lesions all share some common imaging features.

On UECT, fat-rich AMLs show hypoattenuating foci with -10 HUs or less. Contrast-enhanced CT (CECT) is usually not required for the diagnosis of a fat-rich AML, but may be necessary for treatment planning in cases of high risk of bleeding, and embolization is to be considered. On MRI, fat-rich AMLs show variable foci of hyperintensity on both T1-weighted (T1W) and T2-weighted (T2W) imaging that demonstrate signal loss when the fat-suppression technique is applied, thereby confirming the presence of bulk fat and the diagnosis of a fat-rich AML. One should also bear in mind the rare incidence of RCCs containing bulk fat. However, such RCCs are reported to be associated with additional features such as calcifications and necrosis, and usually contain only a small amount of fat relative to tumor size.^{32,33}

Intra-AML aneurysms of 5 mm or more have been shown to be more strongly associated with the likelihood of hemorrhage than overall size.³⁴ In fact, sensitivity and specificity rates of 100% and 86% respectively to predict hemorrhage in the presence of intratumoral aneurysms of 5mm or more compared with a specificity of 38% for the 4-cm AML threshold.³⁴ Hence, in selective cases of vascular lesions with a prediction of risk of bleeding, CECT may be considered to assess intratumor aneurysm and plan for embolization.

Digital subtraction angiography (DSA) can identify AMLs as hypervascular lesions characterized by well-defined hypervascular masses with dense arterial networks observed in the arterial phase. The tortuous vessels have a “sunburst” appearance. In the venous phase, the peripheral vessels have an “onion peel” appearance. Micro- or macro-aneurysms may also be observed with absent arteriovenous shunting.

The CSI MRI technique is used to differentiate fat-poor from fat-invisible AMLs when a renal AML has presents more than -10 Hus on UECT. As clear-cell RCCs, which contain an abundance of intracytoplasmic fat, also show similar CSI MRI characteristics as those of fat-poor AMLs, that is, a tumor-to-spleen SI ratio lower than 0.71 and an SI index greater than 16.5%, this imaging technique alone cannot reliably be used to differentiate fat-poor AMLs from clear-cell RCCs. The qualitative assessment of the lesion may be helpful in this situation, in which fat-poor AMLs are typically mildly hypointense compared with the renal cortex on T2W imaging as opposed to clear-cell RCCs, which are usually hyperintense.^{35,36} The presence of tumor necrosis almost virtually rules out the diagnosis of an AML.³⁵

Prior reports^{36,37} on the use of dynamic contrast-enhanced (DCE) imaging to differentiate minimal-fat AMLs from RCCs have been inconsistent, since it is likely that both fat-poor and fat-invisible AMLs, which could have different DCE imaging characteristics and present histological variations, were considered as a single subtype. Earlier studies have reported minimal-fat AMLs and clear-cell RCCs showing strong early enhancement on DCE CT,³⁶ and homogenous and prolonged enhancement as valuable predictors of minimal-fat AML.³⁷

Fat-invisible AMLs share common imaging features with papillary RCCs, and these two lesions cannot be reliably differentiated from each other based on imaging alone. Both lesions are typically homogeneously hyperattenuating on UECT and hypointense on T2W imaging. Neither show signal loss on CSI MRI due to the paucity of fat. Fat-invisible AMLs may demonstrate homogenous and prolonged enhancement similar to that of papillary RCCs. As such, when a renal lesion demonstrates all of these imaging features, biopsy may need to be considered to differentiate among a fat-invisible AML, an eAML, and a papillary RCC.

The radiological features of AMLs are summarized in ► **Table 2**.^{4,13,18,26,31,32,38}

Biopsy

Radiological identification of AMLs is sufficient for the diagnosis in most cases. Biopsy of the mass lesion may be

Table 2 Radiological features of AML adapted from Vos and Oyen¹³

	Fat-rich AML	Fat-poor AML	Fat-invisible AML
US	Very hyperechoic	Slightly hyperechoic	Isoechoic
UECT	Hypoattenuating	Heterogeneously isoattenuating or hyperattenuating	Homogeneously hyperattenuating
T1-weighted MRI	Signal loss on fat suppression	± signal loss on fat suppression	No signal loss on fat suppression
T2-weighted MRI	Hyperintense	Heterogeneously or homogeneously hypointense	Homogeneously hypointense
CSI MRI	Decrease in signal intensity	Decrease in signal intensity	No decrease in signal intensity

Abbreviations: CSI, chemical-shift imaging; MRI, magnetic resonance imaging; UECT, unenhanced computed tomography; US, ultrasound.

indicated in cases of diagnostic dilemma, such as fat-invisible AML, suspicion of eAML, or RCC and inconclusive imaging results. However, if the lesion has more than 3 cm or there is evidence of massive hemorrhage, then, proceeding with treatment may be more appropriate to avoid further bleeding, and because eAMLs and RCCs are more presumable.^{13,31}

Concerns and Complications: When and Why Is Treatment Indicated?

Many clinicians have asked the question: if sporadic AML is a benign lesion, why and when does it need treatment, and what are the guidelines for management? On the other hand, there are established guidelines^{2,3} for AMLs with hereditary predisposition, which, therefore, are not the focus of our discussion. We will continue to focus on the sporadic cases and their management, reviewing the natural history and management proposed in the literature.

The traditional convention is to consider treatment for AMLs larger than 4 cm. This was first proposed by Oesterling et al.,¹ and has since been debated and reviewed over the years, with one paper¹⁸ suggesting that 70% of AMLs larger than 4 cm are asymptomatic. Several studies emphasize the importance of the size of the vascular component over the size of the fatty mass in predicting the risk of bleeding and need for intervention,^{26,39} with no difference in the growth rate of AMLs shorter or greater than 4 cm.⁴⁰ Overall, more than 90% of AMLs grow very slowly or not at all, regardless of the initial size, while only 9% grow more rapidly, at rates of 0.25 cm per year or more, which may pose a slightly higher risk of rupture and bleeding.⁴⁰ When they measure less than 4 cm, AMLs are rarely symptomatic, but those larger than 4 cm are more likely to be symptomatic (6.6% versus 31.9% respectively).³¹ Thus, the symptoms can provide an indication of tumor growth and, in asymptomatic cases, the degree of vascularity and the presence of intratumor aneurysms measuring 5 mm or more are risk factors for rupture. Other factors indicating the need for treatment are bleeding or increased risk of bleeding, presence of symptoms such as pain or hematuria, eAML variant, and suspicion of malignancy.

The literature suggests that it is reasonable to consider prophylactic treatment in cases considered **high-risk** AMLs and those associated with high-risk factors.

- AML factors:
 - o Patients with intratumor aneurysm measuring 5 mm or more and significant vascularity;^{7,34,41}
 - o AML growth rate higher than 0.25 cm/year;^{40,41}
 - o Severe symptoms;⁴¹ and
 - o Patients with evidence of previously-missed AML rupture, which implies underlying risk factors for future rupture.
- Patient Factors:
 - o Women of or prior to childbearing age (along with patient and lesion-specific risk factors);⁴¹
 - o Patients whose AML rupture or subsequent emergency treatment risks precipitating renal replacement therapy (such as underlying kidney disease, solitary kidney);⁴¹
 - o Patients with intellectual or communication difficulties, in whom symptom evaluation may be challenging; and
 - o Patients with poor physiological reserve but long life expectancy conferring high lifetime risk of rupture.
- Social Factors:
 - o If access to emergency treatment is limited by location or profession (such as residents of rural areas with poor access to emergency medical care; ► **Table 3**).⁴¹

Treatment Options for Sporadic AMLs

Active Surveillance

After confirmation of the diagnosis, if the indications for treatment have not been met, then active surveillance is by and large the most appropriate treatment. There are no current guidelines for the frequency and modality of imaging. It is in fact suggested in the literature⁷ that surveillance imaging of all sporadic AMLs is unlikely to impact management decisions, but preference for a follow-up strategy may help build the evidence gap.

Selective Arterial Embolization

This is minimally invasive and, as such, should be the first-line treatment option (in which diagnosis is certain and treatment is indicated), provided this is technically feasible and the patient is hemodynamically stable. Sometimes

Table 3 Low-risk and high-risk factors for AMLs

Low-risk factors for AML	High-risk factors for AMLs
<ul style="list-style-type: none"> • Postmenopausal women with small AML (< 4cm); • Asymptomatic small AMLs (< 4cm); and • Stable AML size or growth rate < 0.25 cm/year with low vascularity and/or aneurysm < 2.5 mm.⁴¹ 	<ul style="list-style-type: none"> • High vascularity of AML or aneurysm > 5 mm; • AML growth rate > 0.25 cm/year; • Women of childbearing age; • Inadequate access to emergency services; • If failure to treat poses risk of renal replacement therapy in the future; • Learning difficulty or if patient cannot communicate symptoms; • Poor physiological reserve but long life expectancy; and • Severe symptoms.

Abbreviation: AML, angiomyolipoma.

preoperative embolization is considered to reduce the difficulty and complications of surgery.^{7,18}

The complications of embolization include pyrexia, pain, nausea, vomiting, and leucocytosis, which usually occur within the first couple of days of the procedure and are typically self-limiting with supportive management. Embolization of non-target normal renal tissue, renal infarction, and abscess formation are rare but recognized complications. The effects of embolization may vary due to the varying composition of AMLs, with recurrence and repeat bleeding remaining a concern. The literature^{42–44} suggests a varying need for reembolization, ranging from 17% to 37%.

Following treatment, if symptoms persist or recur, repeat imaging (preferably CT angiography) should be performed to assess residual or recurrent tumor volume, residual vascularity, and the presence and size of intratumor aneurysms. As these factors are associated with a risk of hemorrhage, they should be assessed and reported. A tumor which remains unchanged in size but has reduced vascularity and no aneurysms may represent satisfactory treatment response. However, if symptoms persist, then repeat or alternate treatment may be offered. In cases in which the residual AML is poorly vascular, further embolization is probably of limited benefit, and alternate treatments such as ablation or resection may be preferable.

Surgical Management

It includes offering a partial or radical nephrectomy. Ideally, out of the two options, nephron-sparing surgery should be considered, as this will limit nephron loss in the future due to recurrence, multifocal disease or other comorbidities.

Surgery should be considered when an AML is too large for embolization, in the event of failure of the embolization, presence of vascular malformation, or if there is suspicion of malignancy. In uncontrolled hemorrhage and hemodynamically-compromised patients, nephrectomy may be life-saving.^{42,45}

Ablation

Cryoablation, microwave ablation, and radiofrequency ablation are alternatives to the aforementioned invasive procedures. They have been used in selective cases, such as those of solitary kidney or hereditary cases, with an investigation of

the safety and efficacy of the procedure and aiming to preserve renal function.^{43,44} They are more commonly used for RCCs or suspected RCCs, but safety and efficacy have also been reported for AMLs in a small number of patients. The reported average sizes of AMLs treated with these techniques are of ~ 5 cm. Ablation can be applied with percutaneous or laparoscopic techniques, and they work by inducing cell death. These procedures can also be combined with simultaneous biopsies if required.⁷ Little evidence is available on its use on larger or symptomatic AMLs; and a complication rate of 13.3% has been reported in the literature.⁴⁶

Drugs

Drug treatment is not currently an option for the treatment of sporadic AMLs, but it can be offered for the management of hereditary AMLs. Therefore, it will be discussed only briefly. Sirolimus and Everolimus are mTOR inhibitors that interrupt tumor progression and promote regression of the lesion(s). They are offered for asymptomatic AMLs measuring more than 3 cm and associated with LAM and TSC.¹³

Follow-up Imaging

The role of follow-up imaging is uncertain in treated patients who remain asymptomatic, but practitioners and patients are likely to want at least one radiological assessment of posttreatment change. The report should include the residual or recurrent tumor volume, residual vascularity, and presence and size of intratumor aneurysms, as these will help assess the outcome of treatment and if further treatment will be needed, especially if there are persistent or recurrent symptoms.

Conclusion and Recommended Management Pathway for Sporadic AMLs

Renal AMLs are common benign renal masses with varying amounts of fat, blood vessels, and smooth muscle. The fatty component is the characteristic feature that enables diagnosis based on imaging, and the lack of this element presents a diagnostic challenge. Needless to say, establishing the diagnosis is the first step, followed by decision regarding the treatment and surveillance or discharge.

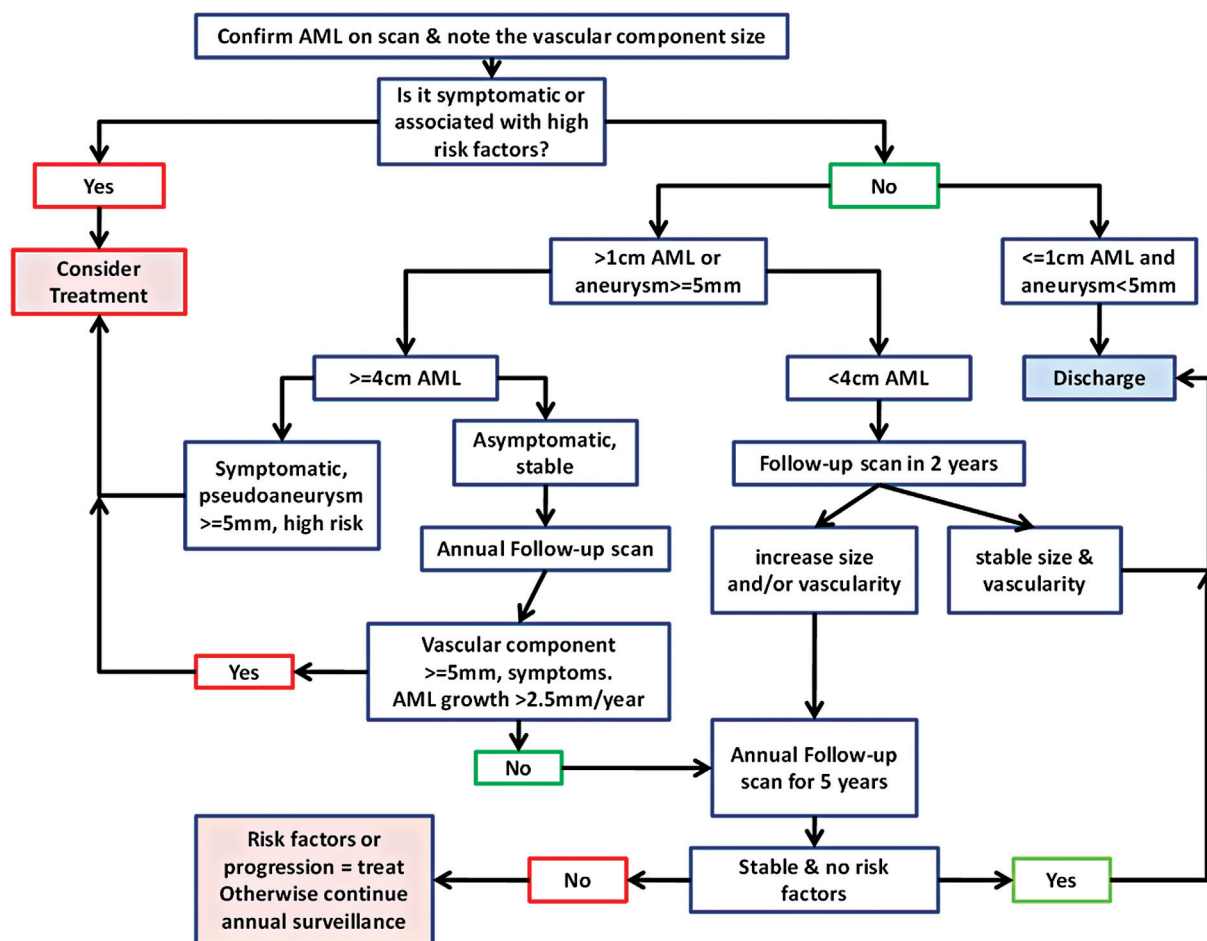


Fig. 1 Flowchart proposed for sporadic AML surveillance.

The natural history of AML is poorly understood, with no strong evidence for the exact cut-off size for treatment. The traditional convention, as proposed by Oesterling et al.,¹ is to consider treatment for AMLs larger than 4 cm, which is a widely accepted size guide used in decision making. However, size alone is not a strong indicator of the risk of bleeding, with various cut-offs, generally larger sizes, suggested over the years. Most sporadic AMLs grow slowly, at an average rate of less than 0.02 cm per year, while 9% show faster growth, of 0.25 cm per year.⁴⁰ The stronger indications for treatment are symptomatic AMLs and high-risk factors for hemorrhage, which justify the prophylactic treatment.

While the choice of treatment is a relatively easier decision to make, there is a lack of surveillance and discharge protocol. Following the present literature review and given the aforementioned characteristics, the benign nature of the lesion and the lack of guidelines, we propose the algorithm shown in ► **Fig. 1** for the management of sporadic AMLs.

Although an US scan may suffice for diagnosis, we also suggest a CT scan at diagnosis and at follow-up in 12 or 24 months to assess the size of the vascular component, as this is the most significant predictor of hemorrhage. The growth and changes noted at this stage can determine the subsequent imaging modality. If the growth rate or vascular component of the AML is significant, symptoms or any of the aforementioned

risk factors develop, then CT is likely to be more helpful, whereas in low-risk cases an US scan may be sufficient.

Following a uniform pathway will help clinicians' decision in management planning and will allow patients to benefit from uniformity of care provision across the region or nation, maintaining a uniform cost-benefit profile. It will also form the basis for a future consistent database to further streamline management and to incorporate into guidelines using the evidence base. Following a standardized surveillance protocol will also allow future prospective studies to evaluate and improve said protocol.

Funding

The authors have no sources of funding to declare.

Conflict of Interests

The authors have no conflict of interests to declare.

References

- Oesterling JE, Fishman EK, Goldman SM, Marshall FF. The management of renal angiomyolipoma. *J Urol* 1986;135(06):1121–1124
- UK guidelines for managing tuberous sclerosis complex, A summary for clinicians in the NHS; Tuberous Sclerosis Association: <https://tuberous-sclerosis.org/wp-content/uploads/2019/10/SummaryofUKguidelinesformanagingTSCFINAL.pdf>

- 3 2012 International TSC Clinical Consensus Conference Recommendations; Tuberous Sclerosis Complex International, A world-wide organisation of tuberous sclerosis complex associations: <http://www.tscinternational.org/wp-content/uploads/2019/01/TSCi-Consensus-Guidelines.pdf>
- 4 Song S, Park BK, Park JJ. New radiologic classification of renal angiomyolipomas. *Eur J Radiol* 2016;85(10):1835–1842. Doi: 10.1016/j.ejrad.2016.08.012
- 5 Shetty AS, Sipe AL, Zulficar M, et al. In-Phase and Opposed-Phase Imaging: Applications of Chemical Shift and Magnetic Susceptibility in the Chest and Abdomen. *Radiographics* 2019;39(01):115–135. Doi: 10.1148/rg.2019180043- **Pubmed**
- 6 Dr Matt A. Morgan and Dr BehrangAmini et al. Renal Angiomyolipoma; Radiopaedia.org; <https://radiopaedia.org/articles/renal-angiomyolipoma?lang=gb>
- 7 Murray TE, Lee MJ. Are We Overtreating Renal Angiomyolipoma: A Review of the Literature and Assessment of Contemporary Management and Follow-Up Strategies. *Cardiovasc Intervent Radiol* 2018;41(04):525–536. Doi: 10.1007/s00270-017-1862-3
- 8 Kothary N. The Angiomyolipoma Conundrum. *J Vasc Interv Radiol* 2016;27(10):1550–1551
- 9 Eble JN, Amin MB, Young RH. Epithelioid angiomyolipoma of the kidney: a report of five cases with a prominent and diagnostically confusing epithelioid smooth muscle component. *Am J Surg Pathol* 1997;21(10):1123–1130. Doi: 10.1097/0000478-199710000-00001
- 10 Maré A, Wickramasinghe S, Ilie V, Mulcahy M. Aggressive Angiomyolipomas: the Clandestine Epithelioid Variant. *Curr Urol* 2016;9(01):54–56. Doi: 10.1159/000442853
- 11 Bharwani N, Christmas TJ, Jameson C, Moat N, Sohaib SA. Epithelioid angiomyolipoma: imaging appearances. *Br J Radiol* 2009;82(984):e249–e252. Doi: 10.1259/bjr/27259024
- 12 Hassan M, El-Hefnawy AS, Elshal AM, Mosbah A, El-Baz M, Shaaban A. Renal epithelioid angiomyolipoma: a rare variant with unusual behavior. *Int Urol Nephrol* 2014;46(02):317–322
- 13 Vos N, Oyen R. Renal Angiomyolipoma: The Good, the Bad, and the Ugly. *J Belg Soc Radiol* 2018;102(01):41. Doi: 10.5334/jbsr.1536
- 14 Fernández-Pello S, Hora M, Kuusk T, et al. Management of sporadic renal angiomyolipoma: A systematic review of available evidence to guide recommendations from European association of urology renal cell carcinoma guidelines panel. *Eur Urol Oncol* 2020;3(01):57–72. Doi: 10.1016/j.euo.2019.04.005
- 15 Samuels JA. Treatment of Renal Angiomyolipoma and Other Hamartomas in Patients with Tuberous Sclerosis Complex. *Clin J Am Soc Nephrol* 2017;12(07):1196–1202. Doi: 10.2215/CJN.08150816
- 16 <https://www.auanet.org/education/auauniversity/education-products-and-resources/pathology-for-urologists/kidney/mesenchymal-and-other-tumors/renal-angiomyolipoma>
- 17 Yeoh ZW, Navaratnam V, Bhatt R, McCafferty I, Hubbard RB, Johnson SR. Natural history of angiomyolipoma in lymphangioleiomyomatosis: implications for screening and surveillance. *Orphanet J Rare Dis* 2014;9:151 <http://www.ojrd.com/content/9/1/151>
- 18 Flum AS, Hamoui N, Said MA, et al. Update on the diagnosis and management of renal angiomyolipoma. *J Urol* 2016;195(4 Pt 1):834–846. Doi: 10.1016/j.juro.2015.07.126
- 19 Johnson SR, Taveira-DaSilva AM, Moss J. Lymphangioleiomyomatosis. *Clin Chest Med* 2016;37(03):389–403. Doi: 10.1016/j.ccm.2016.04.002
- 20 von Ranke FM, Faria IM, Zanetti G, Hochegger B, Souza AS Jr, Marchiori E. Imaging of tuberous sclerosis complex: a pictorial review. *Radiol Bras* 2017;50(01):48–54. Doi: 10.1590/0100-3984.2016.0020
- 21 Pirson Y. Tuberous sclerosis complex-associated kidney angiomyolipoma: from contemplation to action. *Nephrol Dial Transplant* 2013;28(07):1680–1685. Doi: 10.1093/ndt/gft009
- 22 Nese N, Martignoni G, Fletcher CD, et al. Pure epithelioid PEComas (so-called epithelioid angiomyolipoma) of the kidney: A clinicopathologic study of 41 cases: detailed assessment of morphology and risk stratification. *Am J Surg Pathol* 2011;35(02):161–176
- 23 Brimo F, Robinson B, Guo C, Zhou M, Latour M, Epstein JI. Renal epithelioid angiomyolipoma with atypia: a series of 40 cases with emphasis on clinicopathologic prognostic indicators of malignancy. *Am J Surg Pathol* 2010;34(05):715–722
- 24 Oxford Handbook of Urology. 3rd Edition; p245.
- 25 Ahmad M, Arora M, Reddu R, Rizvi I. Wunderlich's syndrome (spontaneous renal haemorrhage). *BMJ Case Rep* 2012;2012:bcr2012006280. Doi: 10.1136/bcr-2012-006280
- 26 Halpenny D, Snow A, McNeill G, Torreggiani WC. The radiological diagnosis and treatment of renal angiomyolipoma-current status. *Clin Radiol* 2010;65(02):99–108. Doi: 10.1016/j.crad.2009.09.014
- 27 Logue LG, Acker RE, Sienko AE. Best cases from the AFIP: angiomyolipomas in tuberous sclerosis. *Radiographics* 2003;23(01):241–246. Doi: 10.1148/rg
- 28 He W, Chevillat JC, Sadow PM, et al. Epithelioid angiomyolipoma of the kidney: pathological features and clinical outcome in a series of consecutively resected tumors. *Mod Pathol* 2013;26(10):1355–1364. Doi: 10.1038/modpathol.2013.72
- 29 Chuang C-K, Lin HCA, Tasi HY, et al. Clinical presentations and molecular studies of invasive renal epithelioid angiomyolipoma. *Int Urol Nephrol* 2017;49(09):1527–1536. Doi: 10.1007/s11255-017-1629-4
- 30 Antic T. Angiomyolipoma. PathologyOutlines.com website. <http://www.pathologyoutlines.com/topic/kidneytumorangiomyolipoma.html>
- 31 Jinzaki M, Silverman SG, Akita H, Nagashima Y, Mikami S, Oya M. Renal angiomyolipoma: a radiological classification and update on recent developments in diagnosis and management. *Abdom Imaging* 2014;39(03):588–604. Doi: 10.1007/s00261-014-0083-3
- 32 Park BK. Renal Angiomyolipoma: Radiologic Classification and Imaging Features According to the Amount of Fat. *AJR Am J Roentgenol* 2017;209(04):826–835. Doi: 10.2214/AJR.17.17973
- 33 Park BK. Renal Angiomyolipoma Based on New Classification: How to Differentiate It From Renal Cell Carcinoma. *AJR Am J Roentgenol* 2019;212(03):582–588
- 34 Yamakado K, Tanaka N, Nakagawa T, Kobayashi S, Yanagawa M, Takeda K. Renal angiomyolipoma: relationships between tumor size, aneurysm formation, and rupture. *Radiology* 2002;225(01):78–82
- 35 Hindman N, Ngo L, Genega EM, et al. Angiomyolipoma with minimal fat: can it be differentiated from clear cell renal cell carcinoma by using standard MR techniques? *Radiology* 2012;265(02):468–477
- 36 Sasiwimonphan K, Takahashi N, Leibovich BC, Carter RE, Atwell TD, Kawashima A. Small (<4 cm) renal mass: differentiation of angiomyolipoma without visible fat from renal cell carcinoma utilizing MR imaging. *Radiology* 2012;263(01):160–168
- 37 Kim JK, Park SY, Shon JH, Cho KS. Angiomyolipoma with minimal fat: differentiation from renal cell carcinoma at biphasic helical CT. *Radiology* 2004;230(03):677–684
- 38 Jinzaki M, Silverman SG, Akita H, Mikami S, Oya M. Diagnosis of renal angiomyolipomas: Classic, Fat-Poor, and Epithelioid types. *Semin Ultrasound CT MR* 2017;38(01):37–46. Doi: 10.1053/j.sult.2016.11.001
- 39 Murray TE, Doyle F, Lee M. Transarterial Embolization of Angiomyolipoma: A Systematic Review. *J Urol* 2015;194(03):635–639. Doi: 10.1016/j.juro.2015.04.081
- 40 Bhatt JR, Richard PO, Kim NS, et al. Natural History of Renal Angiomyolipoma (AML): Most Patients with Large AMLs >4cm Can Be Offered Active Surveillance as an Initial Management Strategy. *Eur Urol* 2016;70(01):85–90. Doi: 10.1016/j.eururo.2016.01.048

- 41 Vaggers S, Rice P, Somani BK, Veeratterapillay R, Rai BP. Evidence-based protocol-led management of renal angiomyolipoma: A review of literature. *Turk J Urol* 2021;47(Suppl 1):S9–S18. Doi: 10.5152/tud.2020.20343
- 42 Seyam RM, Alkhudair WK, Kattan SA, Alotaibi MF, Alzahrani HM, Altaweel WM. The Risks of Renal Angiomyolipoma: Reviewing the Evidence. *J Kidney Cancer VHL* 2017;4(04):13–25. Doi: 10.15586/jkcvhl.2017.97
- 43 Prevoo W, van den Bosch MAAJ, Horenblas S. Radiofrequency ablation for treatment of sporadic angiomyolipoma. *Urology* 2008;72(01):188–191. Doi: 10.1016/j.urology.2008.02.059
- 44 Makki A, Graumann O, Høyer S, et al. Cryoablation of Renal Angiomyolipoma: An Evaluation of Safety and Efficacy. *J Endourol* 2017;31(11):1117–1122. Doi: 10.1089/end.2017.0376
- 45 Urciuoli P, D'Orazi V, Livadoti G, et al. Treatment of renal angiomyolipoma: surgery versus angioembolization. *G Chir* 2013;34(11-12):326–331
- 46 Castle SM, Gorbatiy V, Ekwenna O, Young E, Leveillee RJ. Radiofrequency ablation (RFA) therapy for renal angiomyolipoma (AML): an alternative to angio-embolization and nephron-sparing surgery. *BJU Int* 2012;109(03):384–387