

Quadratus Lumborum Block for Upper Tract Urological Surgery in Pediatric Patients

Bloqueo del cuadrado lumbar para cirugía urológica del tracto superior en pacientes pediátricos

Cassandra Hoffmann¹  Alain Harb¹  Lynn L. Woo²  Jessica H. Hannick² 

¹Division of Pediatric Anesthesia, UH Rainbow Babies and Children's Hospital, Cleveland, Ohio, United States

²Division of Pediatric Urology, UH Rainbow Babies and Children's Hospital, Cleveland, Ohio, United States

Address for correspondence Jessica H. Hannick, MD, MSc, Division of Pediatric Urology, UH Rainbow Babies and Children's Hospital, 11100 Euclid Avenue, RBC Suite 2311, Cleveland, OH 44106, United States (e-mail: jessica.hannick@uhhospitals.org).

Urol Colomb 2022;31(2):e63–e67.

Abstract

Objective Among regional blocks, the quadratus lumborum fascial plane block (QLB) has been well described, but the description of its use and efficacy for pediatric patients undergoing upper abdominal urologic surgery is limited. We present a case series examining the use of the QLB for postoperative pain management in children undergoing upper tract surgery.

Methods From August 2019 to August 2020, through a chart review, we identified 5 patients who had undergone a QLB for upper urinary tract surgery via a flank incision. Posterior QLB was performed after induction of general anesthesia. A single injection of 0.5mL/kg of either 0.25% or 0.5% ropivacaine with 1mcg/kg of clonidine was administered. Patients received fentanyl IV (1 mcg/kg), and acetaminophen IV (15mg/kg) as adjuvants during the operation. Postoperative pain was managed with oral acetaminophen and ibuprofen.

Results The average postoperative pain score during the entire admission was 1, with the lowest being 0 and highest, 3. No administration of rescue narcotics was required in the postanesthesia care unit or on the floor. The average length of stay ranged from 0 to 1 day. No complications associated with the regional QLB were identified.

Conclusions Our series suggests the QLB may be considered as a regional anesthetic option to minimize narcotic requirements for children undergoing upper abdominal urological surgery via flank incision. Additional studies are needed to compare the efficacy of the QLB versus alternate regional anesthetic blocks for upper tract urological surgery via flank incision in children and to determine effective dosing and use of adjuvants.

Keywords

- ▶ regional anesthesia
- ▶ quadratus lumborum block
- ▶ pyeloplasty
- ▶ obstruction of the uteropelvic junction
- ▶ pediatric urology

Resumen

Objetivo Entre los bloqueos regionales, el bloqueo del plano fascial del cuadrado lumbar (BCL) ha sido bien descrito; sin embargo, tiene una descripción limitada de su

received
October 18, 2021
accepted
January 20, 2022

DOI <https://doi.org/10.1055/s-0042-1743510>.
ISSN 0120-789X.
e ISSN 2027-0119.

© 2022. Sociedad Colombiana de Urología. All rights reserved.
This is an open access article published by Thieme under the terms of the Creative Commons Attribution-NonDerivative-NonCommercial-License, permitting copying and reproduction so long as the original work is given appropriate credit. Contents may not be used for commercial purposes, or adapted, remixed, transformed or built upon. (<https://creativecommons.org/licenses/by-nc-nd/4.0/>)
Thieme Revinter Publicações Ltda., Rua do Matoso 170, Rio de Janeiro, RJ, CEP 20270-135, Brazil

uso y eficacia en pacientes pediátricos sometidos a cirugía urológica abdominal superior. Presentamos una serie de casos que examinan el uso del BCL en el manejo del dolor posoperatorio en niños sometidos a cirugía urológica del tracto superior.

Métodos De agosto de 2019 a agosto de 2020, mediante revisión de historias clínicas, se identificaron 5 pacientes sometidos al BCL para cirugía del tracto urinario superior por incisión en el flanco. El BCL posterior se realizó después de la inducción de la anestesia general. Solo se administró una inyección de 0,5 ml/kg de ropivacaína al 0,25% o al 0,5% con 1 mcg/kg de clonidina. Los pacientes recibieron fentanilo IV (1 mcg/kg) y acetaminofén IV (15 mg/kg) como adyuvantes durante la operación. El dolor posoperatorio se manejó con acetaminofén e ibuprofeno oral.

Resultados El puntaje promedio de dolor posoperatorio para todo el ingreso fue de 1, siendo el más bajo 0 y el más alto, 3. No se requirieron administraciones de narcóticos de rescate en la unidad de recuperación postanestésica ni en la planta de hospitalización. La estancia media fue de 0 a 1 día. No se identificaron complicaciones asociadas con el BCL regional.

Conclusiones Nuestra revisión sugiere que el BCL puede ser considerado una opción anestésica regional para minimizar los requerimientos de narcóticos en niños sometidos a cirugía urológica abdominal superior por incisión en el flanco. Se necesitan estudios adicionales para comparar la eficacia de BCL en comparación con la de los bloqueos anestésicos regionales alternativos para la cirugía urológica del tracto superior por incisión en el flanco en niños y para determinar la efectividad de la dosificación y del uso de adyuvantes.

Palabras Clave

- ▶ anestesia regional
- ▶ bloqueo del cuadrado lumbar
- ▶ pieloplastia
- ▶ obstrucción de la unión ureteropélvica
- ▶ urología pediátrica

Introduction

Acute pain in pediatric patients elicits a stress response that can have a deleterious effect on neurological, emotional, and behavioral development. Historically, opioids have been used to treat postsurgical pain; however, they can lead to a myriad of side effects, including apnea, sedation, hypotension, gastric motility dysfunction, tolerance, and withdrawal. Regional anesthesia techniques are gaining traction in a multimodal pain management approach to decrease opioid use and provide effective analgesia. Fascial plane blocks are replacing neuraxial methods (caudal) for postoperative analgesia due to ease of use with ultrasound guidance and increased duration of action.¹ Emerging literature² supports the feasibility, efficacy, and safety of pediatric regional anesthesia in the hands of experienced practitioners. The quadratus lumborum fascial plane block (QLB) is one of the more recently described truncal blocks that provides analgesia over a large truncal plane. The QLB provides effective truncal sensory blockade from dermatomal levels T6 to T12 for abdominal surgery. The QLB has been well described in the adult literature as well as the pediatric surgical literature.³ To date, there is limited description of its use and efficacy for pediatric patients undergoing upper abdominal urologic surgery.^{1,4} Herein we present a case series examining the use of the QLB for postoperative pain management in pediatric patients undergoing upper tract urological surgery via flank incision.

Methods

Following approval from the Institutional Review Board, the electronic medical record from our institution was queried from August 2019 to August 2020, to identify pediatric patients aged between 0 and 17 years who underwent open upper urinary tract surgery via a flank incision. Patients undergoing upper urinary tract surgery via a laparoscopic approach were excluded due to the different incisions used in laparoscopy. All patients undergoing open upper urinary tract surgery during the defined study period were offered and consented to undergo a QLB. Five patients were identified (►Table 1).

Upon induction of general anesthesia, patients received fentanyl IV (1 mcg/kg) and acetaminophen IV (15mg/kg) during the operation. After induction, a posterior QLB was performed. Patients were placed in position for their pyeloplasty, as dictated by the surgeon, and the skin site was prepped. A high-frequency (4.2–13 MHz) linear ultrasound probe was placed transversely in the midaxillary line to visualize the muscular plane and moved posteriorly until the aponeurosis of the transversus abdominis became visible and the quadratus lumborum (QL) muscle was identified. Using an in-plane approach, a 22-gauge, 50-mm echogenic needle was inserted and advanced posteriorly to the interfascial plane between the QL muscle and the thoracolumbar fascia (►Fig. 1). Hydrodissection was performed to confirm needle position and, after negative aspiration, a single injection of 0.5mL/kg of either 0.25% or 0.5% ropivacaine

Table 1 Characteristics of pediatric patients undergoing upper urinary tract urological surgery

Age/gender	Weight (kg)	BMI (kg/m ²)	ASA score	Diagnosis	Procedure	Incision	Surgical Technique	Postop drains	EBL (mL)	Operative time (minutes)
2 years/Female	14.3	16.2	2	L UPJO	Left open dismembered pyeloplasty	Flank	Spread muscles	Salle nephro-ureteral stent	5	173
8 months/Female	8.3	17.7	2	R UPJO	Right open ureterocalicostomy	Flank	Split muscles	JJ ureteral stent, Penrose, foley	5	227
7 months/Male	8.7	17.5	2	L UPJO	Left open dismembered pyeloplasty	Flank	Spread muscles	Salle nephro-ureteral stent	2	160
7 years/Male	27.6	16.3	2	L UPJO	Left open dismembered pyeloplasty	Flank	Spread muscles	Salle nephro-ureteral stent	4	163
5 years/Male	23	14.3	2	L UPJO	Left open dismembered pyeloplasty	Flank	Spread muscles	Salle nephro-ureteral stent	5	173

Abbreviations: ASA, American Society of Anesthesiologists; BMI, Body Mass Index; EBL, estimated blood loss; L UPJO, left ureteropelvic junction obstruction; Postop, postoperative; R UPJO, right ureteropelvic junction obstruction.

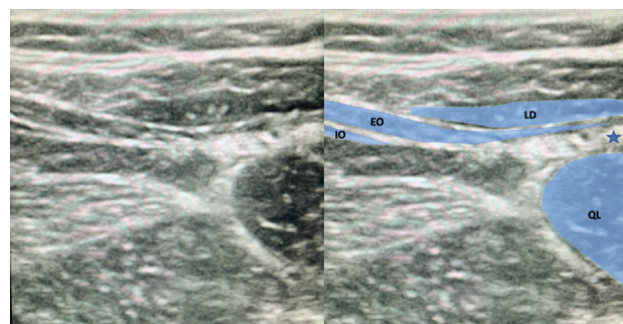


Fig. 1 Ultrasound image of the anatomical structures and local anesthetic injection point for posterior QLB. Abbreviations: EO, external oblique muscle; IO, internal oblique muscle; LD, latissimus dorsi muscle; QL, quadratus lumborum muscle. Note: *Injection point.

(concentration chosen at practitioner’s discretion) with 1mcg/kg of clonidine was administered (► **Fig. 1**).

Per hospital protocol, postoperative pain scores were obtained every 20 minutes in the postanesthesia care unit (PACU) and every 4 hours on the inpatient floor according to age-appropriate 10-point scales (Children’s Revised Impact of Event Scale [CRIES] for patients aged < 1 year; Face, Legs, Activity, Cry, Consolability [FLACC] for those aged between 1 and 5 years; and the Wong–Baker Faces Pain Rating Scale [FACES] for patients aged between 5 and 8 years) (► **Table 2**). Postoperative pain was managed with oral acetaminophen and ibuprofen. Oral narcotics were available for breakthrough pain scores > 4.

Results

From August 2019 to August 2020, 2 pediatric urologists within a single quaternary care institution performed a total of 12 upper urinary tract surgeries for management of primary or secondary obstruction of the ureteropelvic junction. Of these cases, five patients submitted to open flank surgery who underwent a preoperative unilateral QLB were identified. No QLB had to be aborted or crossed over to an alternative block. The performance of the block technique took less than ten minutes for all patients. All patients had either an internalized JJ ureteral stent or Salle nephroureteral stent. One patient had a postoperative foley catheter and Penrose drain.

The average postoperative pain score during the admission was 1, with the lowest being 0 and highest, 3. All blocks were considered successful because no patient required narcotics in the postoperative period. The average length of stay was of 0 to 1 day. No complications (such as hypertension, infection, hematoma) or technical difficulties associated with the regional QLB were identified.

Discussion

The present series supports the notable trends demonstrated elsewhere toward the use of regional anesthesia. The transversus abdominus plane (TAP) block has been described for

Table 2 Block and postoperative pain characteristics

Age/gender	Duration of the performance of the block technique (minutes)	Intraoperative IV adjuvants	Postoperative pain scores
2 years/Female	7	Tylenol 300 mg	2, 0, 0, 0, 0, 0, 0, 0, 0, 0, 0, 0, 0
8 months/Female	6	Tylenol 120 mg	2, 0, 0, 1, 0, 0, 0, 0, 1, 1
7 months/Male	9	Tylenol 80 mg	0, 2, 0
7 years/Male	3	Tylenol 400 mg	2, 0, 2, 2, 2, 0, 2, 2
5 years/Male	4	Tylenol 345 mg	0, 3, 1, 2, 1, 0, 0, 3

pediatric abdominal surgeries, but the comparison by Lorenzo et al.⁵ of the TAP block to surgeon-administered infiltration in children undergoing pyeloplasty was equivocal. The QLB is a fascial plane block that provides sensory blockade from T6 to L1 with a single injection. The levels for a typical flank incision, as used in the present series, would be dermatomal levels T7 to T10. In comparison to the TAP block, Öksüz et al.⁶ describe that the QLB provides longer and more effective postoperative analgesia compared with the TAP block for children undergoing lower abdominal surgery. The QLB has been found to be equivalent to the erector spinae plane block for pediatric abdominal surgery; however, the QLB was chosen due to the ease of performing it in the planned surgical position.⁷ A transvertebral block was not considered by the surgical and anesthesia teams, as the duration of this block is shorter than that of the QLB, and, while low, potential risks associated with the technique are significant, such as pleural puncture and pneumothorax.⁸ In the present series, we observed an average postoperative pain score of 1. The lack of response to the initial incision and the lack of need for narcotics following induction strongly suggest that dermatomes were not missed by the QLB, and that pain was adequately controlled.

Most regional anesthesia studies decrease the concentration of the ropivacaine used in fascial plane blocks to increase the volume that can be utilized, but this may sacrifice block density. The deposition of a high volume and high concentration of local anesthetic solution posterior to the QL muscle in the middle of the thoracolumbar fascia provides a dense truncal block, while the addition of clonidine prolongs the duration of the block.^{9,10} In the present case series, the local anesthetic concentration injected for the procedure was increased, but within standard maximum dosing guidelines according to patient weight. Utilizing such dosing with the pediatric patient population enables the performance of an opioid-sparing technique, potentially leading to a denser blockade, and providing effective analgesia for 24 hours following surgery. The duration of the block could not be objectively measured in the present series, but it is described to have analgesic effects lasting up to 24 hours. Future studies will aim to assess the effect of varying local anesthetic concentration on pain control and durability after QLB, as well as whether the block may be optimized with the addition of alternative adjuncts such as dexmetomidine.¹¹

The limitations of the present case series include its small sample size and retrospective nature, which is inherent to this type of study. The small number of cases identified during this one-year period is likely directly related to the onset of the COVID-19 pandemic in March 2020, the mid-point of the period reviewed, which negatively impacted both patients interacting with health care and the availability of operating rooms to the surgeons involved in the present study. Additionally, there was varied dosing concentrations used for the blocks, as well as multiple practitioners performing the blocks in a non-standardized fashion, all of which may have introduced bias in the observed results.

Despite its limitations, the present series serves to demonstrate the feasibility of performing QLBs in this patient population. Future randomized, controlled studies are needed to establish the efficacy of pain control for QLB versus in-field surgeon-administered infiltration, as well as the optimal local anesthetic concentration and volume, and potential added benefits from the use of local anesthetic adjuvants.

Conclusion

The present case series demonstrates the utility of the QLB in minimizing narcotic requirements for pediatric patients undergoing upper abdominal urological surgery, both intraoperatively and postoperatively. Randomized, controlled studies are necessary to compare the efficacy of the QLB versus surgeon-administered infiltration for upper abdominal surgery in pediatric patients, as well as to determine effective dosing and use of adjuvants.

Conflict of Interests

The authors have no conflict of interests to declare.

Acknowledgment

The authors would like to acknowledge Dr. Elie Geara for his assistance with the early conceptualization of this work.

References

- 1 Sato M. Ultrasound-guided quadratus lumborum block compared to caudal ropivacaine/morphine in children undergoing surgery for vesicoureteric reflex. *Paediatr Anaesth* 2019;29(07):738–743. Doi: 10.1111/pan.13650

- 2 Vargas A, Sawardekar A, Suresh S. Updates on pediatric regional anesthesia safety data. *Curr Opin Anaesthesiol* 2019;32(05): 649–652. Doi: 10.1097/aco.0000000000000768
- 3 Srivastava D, Verma R, Singh TK, et al. Ultrasound-guided anterior quadratus lumborum block for postoperative pain after laparoscopic pyeloplasty: A randomized controlled trial. *Anesth Essays Res* 2020;14(02):233–238. Doi: 10.4103/aer.aer_45_20
- 4 Baidya DK, Maitra S, Arora MK, Agarwal A. Quadratus lumborum block: an effective method of perioperative analgesia in children undergoing pyeloplasty. *J Clin Anesth* 2015;27(08):694–696. Doi: 10.1016/j.jclinane.2015.05.006
- 5 Lorenzo AJ, Lynch J, Matava C, El-Beheiry H, Hayes J. Ultrasound guided transversus abdominis plane vs surgeon administered intraoperative regional field infiltration with bupivacaine for early postoperative pain control in children undergoing open pyeloplasty. *J Urol* 2014;192(01):207–213. Doi: 10.1016/j.juro.2014.01.026
- 6 Öksüz G, Bilal B, Gürkan Y, et al. Quadratus Lumborum Block Versus Transversus Abdominis Plane Block in Children Undergoing Low Abdominal Surgery: A Randomized Controlled Trial. *Reg Anesth Pain Med* 2017;42(05):674–679. Doi: 10.1097/aap.0000000000000645
- 7 Aksu C, Şen MC, Akay MA, Baydemir C, Gürkan Y. Erector Spinae Plane Block vs Quadratus Lumborum Block for pediatric lower abdominal surgery: A double blinded, prospective, and randomized trial. *J Clin Anesth* 2019;57:24–28. Doi: 10.1016/j.jclinane.2019.03.006
- 8 Page EA, Taylor KL. Paravertebral block in paediatric abdominal surgery—a systematic review and meta-analysis of randomized trials. *Br J Anaesth* 2017;118(02):159–166
- 9 Emelife PI, Eng MR, Menard BL, et al. Adjunct medications for peripheral and neuraxial anesthesia. *Best Pract Res Clin Anaesthesiol* 2018;32(02):83–99. Doi: 10.1016/j.bja.2018.11.030
- 10 Sinha C, Kumar B, Bhadani UK, Kumar A, Kumar A, Ranjan A. A comparison of dexamethasone and clonidine as an adjuvant for caudal blocks in pediatric urogenital surgeries. *Anesth Essays Res* 2016;10(03):585–590. Doi: 10.4103/0259-1162.186604
- 11 Abdellatif AA, Kasem AA, Bestarous JN, Toaima TN, Ali MM, Shokri H. Efficacy of dexmedetomidine as an adjuvant to Quadratus lumborum block for pediatrics undergoing laparoscopic pyeloplasty. A prospective randomized double blinded study. *Minerva Anesthesiol* 2020;86(10):1031–1038. Doi: 10.23736/s0375-9393.20.14298-6