

Performance of the TWIST Score in Patients with Testicular Torsion that Present to the Emergency Department

Desempeño del puntaje TWIST en pacientes con torsión testicular que se presentan al Departamento de Emergencias

Catalina Barco-Castillo¹ Daniel Sánchez² Nicolás Fernández^{3,4}

¹ Department of Urology, Hospital Universitario Fundación Santa Fe de Bogotá, Colombia and Universidad de los Andes School of Medicine, Bogotá DC, Colombia

² School of Medicine, Universidad de los Andes, Bogotá DC, Colombia

³ Department of Urology, Hospital Universitario Fundación Santa Fe de Bogotá, Universidad de los Andes School of Medicine, Bogotá DC, Colombia

⁴ Division of Urology, Seattle Children's Hospital University of Washington, Seattle, Washington, United States

Address for correspondence Nicolas Fernandez, MD, PhD, Cr 7 118 09, Renal Unity, Third Floor, Urology Clinic (e-mail: jn.fernandez@uniandes.edu.co).

Urol Colomb 2020;29:225–230.

Abstract

Objective Testicular torsion (TT) is an emergency with an incidence of 1:1,500 in patients < 18 years old. Irreversible changes in the testicular parenchyma may happen. The Testicular Workup for Ischemia and Suspected Torsion (TWIST) questionnaire evaluates signs and symptoms to determine the risk of TT and improve the time of management. The aim of the present study was to compare the intraoperative findings of patients with TT with the result of the preoperative TWIST questionnaire.

Methods A cohort of 33 pediatric patients that consulted to the emergency room was evaluated. The TWIST questionnaire was applied in the first approach. Imaging studies, time to the operating room (OR) and intraoperative findings were evaluated. Theoretical and real findings were compared.

Results The median age was 13 years old (interquartile range [IQR] 10–15 years old). Edema and scrotal inflammation was the most frequent finding (42.4%), followed by testicular induration (21.2%), nausea and vomiting (15.2%), and horizontal testicle and absence of cremasteric reflex (9.1%). The TWIST stratification was 3% high-risk, 18.2% intermediate-risk and 78.8% low-risk. Testicular Doppler ultrasound was performed in 93.9% of the patients: vascular congestion was found in 21.9%. A total of 30.3% of the kids were taken to surgery after 163 minutes (± 116.5). Intraoperative diagnosis of TT was confirmed in the high-risk patient, in 33.3% of the intermediate-risk, and in 50% of the low-risk. The receiver operating characteristic (ROC) curve showed an accuracy of 60% ($p = 0.602$).

Conclusions The TWIST questionnaire in the first approach allows to take the high-risk patients immediately to the OR. However, it might not be a reliable tool for diagnosis of TT in intermediate and low-risk patients.

Keywords

- ▶ testicular torsion
- ▶ testicular pain
- ▶ emergency room
- ▶ TWIST score
- ▶ urological emergency
- ▶ pediatric urology

received
January 9, 2020
accepted
April 15, 2020

DOI <https://doi.org/10.1055/s-0040-1712937>.
ISSN 0120-789X.
e ISSN 2027-0119.

Copyright © 2020, Sociedad Colombiana de Urología. Publicado por Thieme Revinter Publicações Ltda., Rio de Janeiro, Brazil. Todos los derechos reservados.

License terms



Resumen

Palabras clave

- ▶ torsión testicular
- ▶ dolor testicular
- ▶ departamento de emergencias
- ▶ cuestionario TWIST
- ▶ emergencias urológicas
- ▶ urología pediátrica

Objetivo La torsión testicular (TT) es una emergencia con incidencia de 1:1.500 en pacientes menores de 18 años. Pueden ocurrir cambios irreversibles en el parénquima testicular. El cuestionario TWIST evalúa signos y síntomas para determinar el riesgo de TT y mejorar los tiempos de atención. El objetivo de este estudio fue comparar los hallazgos intraoperatorios de los pacientes con el resultado del TWIST preoperatorio.

Métodos Se evaluó una cohorte de 33 pacientes pediátricos que consultaron al Departamento de Emergencias. Se aplicó el cuestionario TWIST en la primera aproximación. Estudios imagenológicos, tiempo de entrada a salas de cirugía y hallazgos intraoperatorios también fueron evaluados. Se compararon los hallazgos teóricos y reales.

Resultados La mediana de edad fue de 13 años (rango intercuartil [RIQ]: 10–15). Edema e inflamación escrotal fueron los hallazgos principales, (42,4%) seguidos de induración testicular (21,2%), náusea y vómito (15,2%), y testículo horizontal y ausencia del reflejo cremastérico (9,1%). Estratificación TWIST: 3% alto riesgo, 18,2% intermedio, y 78,8% bajo. Se realizó Doppler testicular en 93,9% de los pacientes: se encontró congestión vascular en 21,9%. Se operaron 30,3% de niños tras 163 minutos ($\pm 116,5$). En el intraoperatorio se confirmó TT en el paciente de alto riesgo, en 33,3% de intermedio, y en 50% de bajo riesgo. La curva de característica operativa del receptor (COR) evidencia una exactitud de 60% ($p = 0.602$).

Conclusiones El cuestionario TWIST en la primera aproximación es útil para operar inmediatamente pacientes de alto riesgo. Sin embargo, no ofrece un alto nivel de confianza para el diagnóstico de TT en pacientes de intermedio y bajo riesgo.

Introduction

Testicular torsion (TT) is one of the more frequent urological emergencies, affecting 3.8/100,000 males < 18 years old worldwide.¹ Testicular torsion happens after a torsion of the testis over the spermatic cord that causes hemodynamic changes: venous congestion and blood flow reduction that end up in tissue ischemia and posterior testicular necrosis. These time-dependent changes end in functional loss of the organ and the need to perform an orchiectomy.² The testis salvage times include 90–100% of patients if they undergo surgery in the first 6 hours of presentation, 50% between 6 and 12 hours and < 10% after 24 hours.³

The TT diagnosis is clinical and must be suspected in every patient with acute scrotum.^{3,4} The evaluation should include sudden unilateral testicular pain associated with nausea and vomit.^{3,4} Other findings include unilateral elevation of the testis, abnormal horizontal orientation, thickening of the spermatic cord, absences of the cremasteric reflex and erythema.³

Barbosa et al created the Testicular Workup for Ischemia and Suspected Torsion (TWIST) Score, which allows to stratify patients during its first approach in the emergency room (ER) in low-, intermediate- and high-risk groups according to the symptomatology, so the management is more accurate and faster in the patient with diagnosis of TT.^{5,6} Also, the need for Doppler ultrasound might be lower and the costs of the attention can be reduced.

The aim of the present study was to compare the risk of the patients according to the initial results of the TWIST Score and the intraoperative findings.

Methods

The study protocol was approved by the Institutional Ethics Committee of the Hospital Universitario Fundación Santa Fe de Bogotá, Bogotá DC, Colombia, under the tenets of the Declaration of Helsinki. A cohort of 33 patients < 18 years old who consulted to the ER due to testicular pain was evaluated between January and December of 2018. Patients with a history of > 24 hours of pain were excluded. All of the patients had a first evaluation in the pediatric ER by a pediatrician followed by a consultation of the pediatric urologist.

The clinical records of each patient were reviewed and recorded in Microsoft Excel 2016 for MacOS (Microsoft Corporation, Redmond, WA, USA). The whole symptomatology, time of evolution, and need for ultrasonography and for surgical management and its findings were evaluated. The TWIST Score (– Fig. 1) was theoretically and retrospectively applied as a first approach evaluation to stratify each patient in a group of TT risk. Each group of risk should follow an algorithm: 1) High-risk patients must be taken immediately to the operating room (OR) by the pediatric urologist; 2) Intermediate-risk should be taken to Doppler ultrasound and evaluated by the pediatric urologist; and 3) Low-risk patients

Signs or symptoms	Present (yes/no)	Score	Assigned score
Scrotal edema or inflammation			2
Induration of the testis			2
Elevated or horizontal testis			1
Nausea or vomiting			1
Absent cremasteric reflex			1
TOTAL			

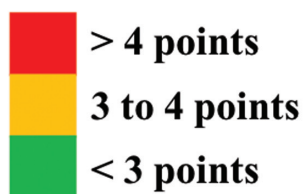


Fig. 1 TWIST Score used for evaluation in the first approach of the patient with acute scrotum.

might be evaluated by the pediatrician who should determine the management (►Fig. 2).⁵

Once the patients were stratified, a comparison between the assumed and the real findings and management was performed using Chi-squared tests for categorical variables. The Shapiro-Wilk normality test was performed in all continuous variables to report them as average \pm standard deviation (SD) in parametric ones and in median (interquartile range) in nonparametric variables. A receiver operating characteristic (ROC) curve analysis was performed for each group of risk. All of the analyses were performed in SPSS Statistics for MacOS, Version 25.0 (IBM Corp., Armonk, NY, USA).

Results

The median age of the cohort was 13 years old (10–15 years old). Only 2 patients (6.1%) had a previous history of acute scrotum (torsion-detorsion syndrome). Within the signs and symptoms evaluated, 14 (42.4%) patients presented with edema or scrotal inflammation, 7 (21.2%) had testicular indu-

ration, 5 (15.2%) nausea and vomiting, and 3 (9.1%) presented horizontal testis and absence of cremasteric reflex.

According to the TWIST Score, the high-risk group had 1 (3%) patient, the intermediate-risk group had 6 (18.2%), and the low-risk group had 26 (78.8%). Doppler ultrasound was performed in 31 (93.9%) patients, and 7 (21.2%) presented vascular congestion. A total of 10 (30.3%) patients were taken to the OR within an average time of 163 ± 116.5 minutes. When stratified by risk group, the high-risk patient underwent surgery, so did 5 (83.3%) patients of the intermediate-risk group and 4 (15.4%) of the low-risk group. A positive finding of TT was reported in 5 (15.2%) patients: 1 (100%) in the high-risk, 2 (33.3%) in the intermediate-risk and 2 (7.7%) in the low-risk groups. All data are summarized in ►Table 1.

The ROC analysis for the overall patients showed an accuracy of 60% ($p = 0.602$). When evaluated by group of risk, the high-risk could not be evaluated due to the small sample, the intermediated-risk showed an accuracy of 66.7% ($p = 0.564$) and the low-risk presented an accuracy of 50% ($p = 1.000$) (►Fig. 3) (►Table 2).

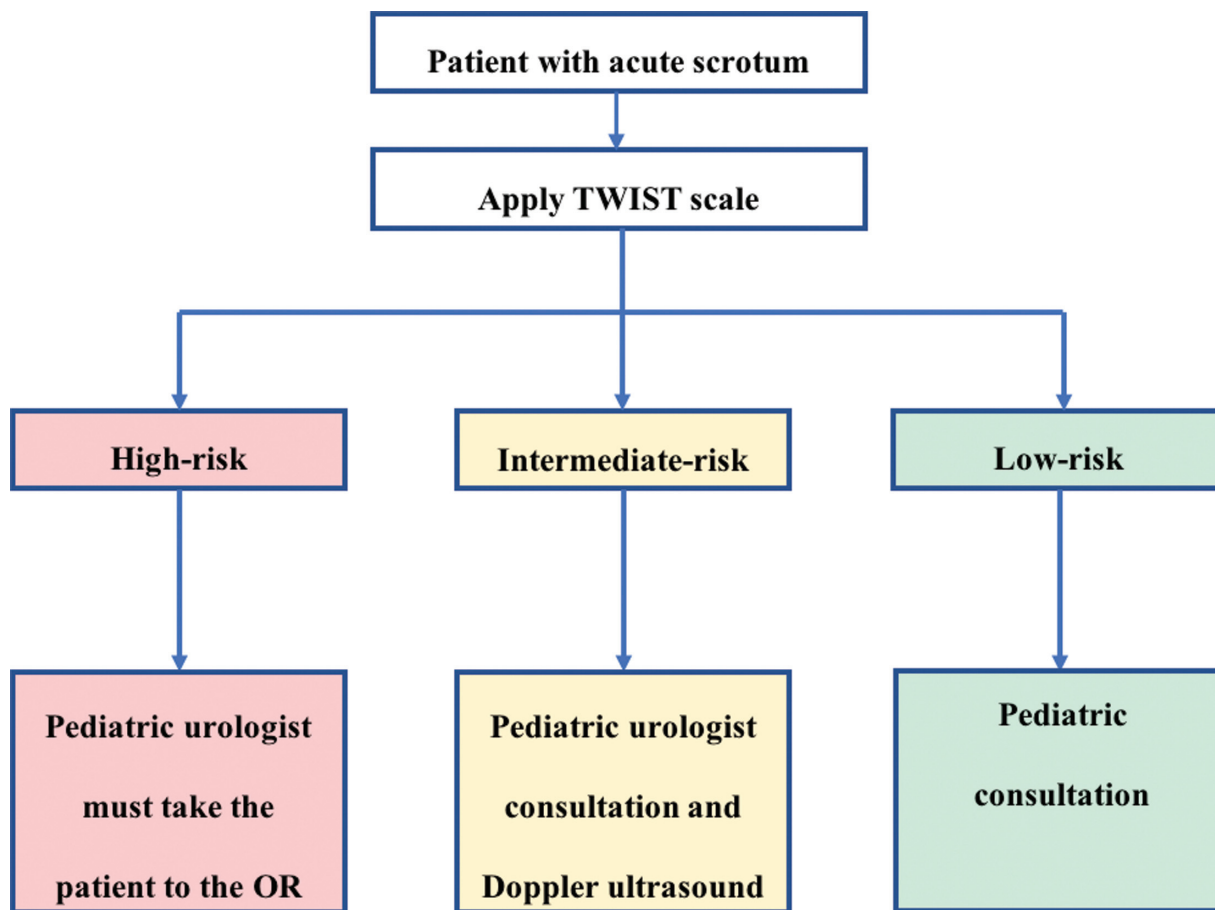


Fig. 2 Algorithm for management of testicular torsion according to the risk group.

Table 1 Characteristics of the patients

Variables	Overall n = 33	High-risk n = 1	Intermediate-risk n = 6	Low-risk n = 26
<i>Baseline characteristics</i>				
Age (years)*	13 [10–15]	12 [12–12]	14 [10.75–16]	12.5 [10–15]
History of previous diagnosis of acute scrotum ^{&}	2 (6.1)	0 (0)	0 (0)	2 (7.7)
<i>TWIST Scale</i>				
Scrotal edema or inflammation ^{&}	14 (42.4)	1 (100)	6 (100)	7 (26.9)
Induration of the testis ^{&}	7 (21.2)	1 (100)	4 (66.7)	2 (7.7)
Elevated or horizontal testis ^{&}	3 (9.1)	0 (0)	1 (16.7)	2 (7.7)
Nausea or vomiting ^{&}	5 (15.2)	1 (100)	1 (16.7)	3 (11.5)
Absent cremasteric reflex ^{&}	3 (9.1)	1 (100)	0 (0)	2 (7.7)
<i>Diagnosis and management</i>				
Doppler ultrasound ^{&}	31 (93.9)	1 (100)	6 (100)	24 (92.3)
Vascular congestion finding ^{&}	7 (21.2)	1 (100)	4 (66.7)	2 (7.7)
Need for surgery ^{&}	10 (30.3)	1 (100)	5 (83.3)	4 (15.4)
Testicular torsion intraoperative finding ^{&}	5 (15.2)	1 (100)	2 (33.3)	2 (7.7)
Time to operating room (minutes) [§]	163 ± 116.5	89 ± 0	166 ± 138.4	177.8 ± 114.1

*Reported as median [IQR].

§Reported as average ± standard deviation.

&Reported as n (%).

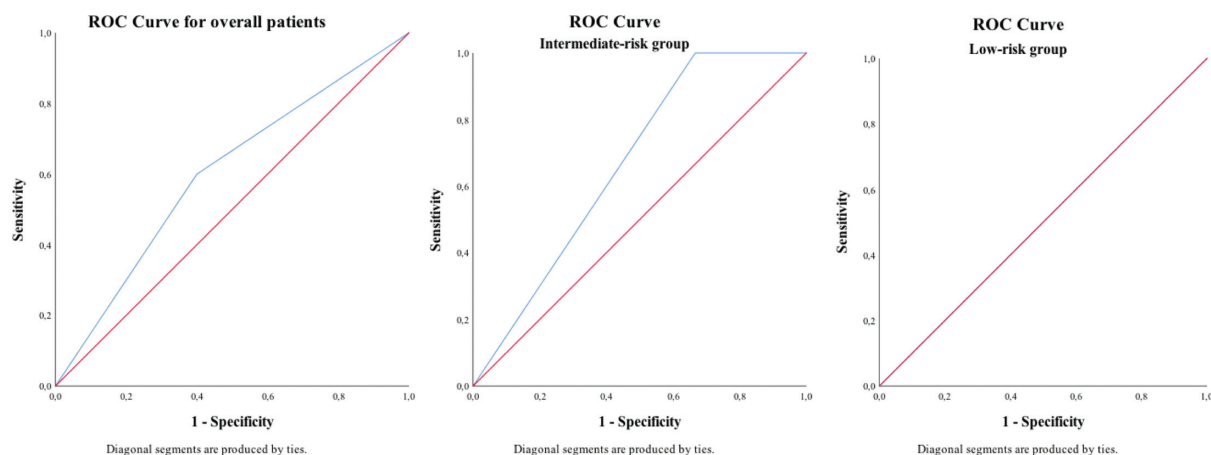


Fig. 3 ROC curves for overall patients and intermediate-risk and low-risk groups.

Table 2 ROC curves for testicular torsion diagnosis with the TWIST Scale

Variables	Area	95%CI	p-value
Overall patients	0.600	0.232–0.968	0.602
Intermediate-risk group	0.667	0.156–1.000	0.564
Low-risk group	0.500	0.000–1.000	1.000

Abbreviation: CI, confidence interval.

Discussion

Testicular torsion is an emergency that should be diagnosed and treated as soon as possible due to the testis loss risk related to the time of attention.^{7–9} Barbosa et al first described the TWIST score in 338 patients and showed a negative predictive value (NPV) and a positive predictive value (PPV) of 100%; however, it was not validated.⁵ In 2016, Sheth et al validated it in 128 patients and concluded same predictive values that Barbosa et al in patients Tanner 3–5.⁶ Also, they recommended Doppler ultrasound in all patients Tanner 1 and 2 regardless of the TWIST score.⁶ In our study, we evaluated all patients without taking into account the Tanner score due to the necessity of using the tool in the whole population.

In this cohort, there was only one patient with high-risk of TT that presented vascular congestion in the Doppler ultrasound and was taken to surgery, where the diagnosis was confirmed. We believe this group is easy to identify due to the high number of signs and symptoms they present and to the fact that they score more points in the TWIST. This is comparable to the 39 (11.5%) of high-risk patients in the Barbosa et al cohort, in which 100% presented an intraoperative diagnosis of TT.⁵

The reason why our biggest concern is the use of the TWIST Score in the low and intermediate-risk patients. In the study by Barbosa et al, there were 65 (19.2%) intermediate-risk patients, of whom 12 (18.46%) had TT, and 234 (69.2%) low-risk patients, of which none presented TT. Also, Sheth et al presented 57 (44.53%) patients in the intermediate-group, in which 15

(26.32%) had a positive diagnosis, and 40 (31.25%) in the low-risk group in which none presented the diagnosis of TT.⁶

For our intermediate-risk group, we had 6 (18.2%) patients, of whom 100% underwent Doppler ultrasound and only 4 (66.7%) showed vascular congestion. A total of 5 (83.3%) patients were taken to surgery and only 2 (33.3%) were diagnosed with TT. This evidences an accuracy of 66.7% ($p = 0.564$) in the ROC curve. This is concerning because of the need for Doppler ultrasound and still the need for intraoperative confirmation of the diagnosis, does not reduce the costs in the attention for the guardians or the health care system, nor the times to the OR and the testis salvage rate will not increase.

As in previously mentioned studies,^{5,6} the low-risk group represents the majority of the patients, in this case 26 (78.8%). Out of the total of patients, 24 (92.3%) underwent Doppler ultrasound and 2 (7.7%) patients presented a positive finding that was confirmed intraoperatively even when stratified in the low-risk group. We attribute this finding to the high socioeconomic and educational status population we evaluated, who seeks faster an ER consultation when the signs and symptoms may not be severe yet. The accuracy of the TWIST Score in the low-risk population was of 50% ($p = 1.000$) and makes us question about its reliability and its use in this patients.

The limitations of the present study include the initial approach performed by a pediatrician and not by a pediatric urologist, who has more experience in the evaluation of these patients. Nonetheless, it has been established that the TWIST score can be assessed by personnel different than the urologist. Also, the small cohort evaluated and the high socioeconomic and educational status of the patients biases our study. The same study performed in more centers of the city and of the country will bring us results that we can compare with to determine the reliable use of the TWIST Score in Colombia.

Conclusions

Even when the TWIST questionnaire in the first approach allows to take the high-risk patients immediately to the OR,

reducing times of attention and allowing to reduce costs in Doppler ultrasound in these patients, it might not be a reliable tool for diagnosis of TT in intermediate and low-risk patients.

Conflict of Interests

The authors have no conflict of interests to declare.

References

- 1 Fernandez N, Medina-Rico M, Rincon LF, Perez J. Description of Clinical Factors Associated with Testicular Torsion. *Urol Colomb* 2018;27:167–173
- 2 Howe AS, Vasudevan V, Kongnyuy M, et al. Degree of twisting and duration of symptoms are prognostic factors of testis salvage during episodes of testicular torsion. *Transl Androl Urol* 2017;6(06):1159–1166
- 3 Afsarlar CE, Ryan SL, Donel E, et al. Standardized process to improve patient flow from the Emergency Room to the Operating Room for pediatric patients with testicular torsion. *J Pediatr Urol* 2016;12(04):233.e1–233.e4
- 4 Sharp VJ, Kieran K, Arlen AM. Testicular torsion: diagnosis, evaluation, and management. *Am Fam Physician* 2013;88(12):835–840
- 5 Barbosa JA, Tiseo BC, Barayan GA, et al. Development and initial validation of a scoring system to diagnose testicular torsion in children. *J Urol* 2013;189(05):1859–1864
- 6 Sheth KR, Keays M, Grimsby GM, et al. Diagnosing Testicular Torsion before Urological Consultation and Imaging: Validation of the TWIST Score. *J Urol* 2016;195(06):1870–1876
- 7 Zhao LC, Lautz TB, Meeks JJ, Maizels M. Pediatric testicular torsion epidemiology using a national database: incidence, risk of orchiectomy and possible measures toward improving the quality of care. *J Urol* 2011;186(05):2009–2013
- 8 Visser AJ, Heyns CF. Testicular function after torsion of the spermatic cord. *BJU Int* 2003;92(03):200–203
- 9 Cost NG, Bush NC, Barber TD, Huang R, Baker LA. Pediatric testicular torsion: demographics of national orchiopexy versus orchiectomy rates. *J Urol* 2011;185(6, Suppl):2459–2463